



Double IC Valve: A Rare, Surprising Sequelae of Ileocecal Tuberculosis

Dipankar Das*; Vinod Kumar; V K Dixit; Aakash Shah

Department of Gastroenterology, Institute of Medical sciences, Banaras Hindu University, India.

***Corresponding Author(s): Dr Dipankar Das**

DM Resident Department of Gastroenterology, Institute of Medical sciences, Banaras Hindu University, India.

Email: Dipankar.das304@gmail.com

Received: Mar 20, 2023

Accepted: Apr 10, 2023

Published Online: Apr 17, 2023

Journal: Annals of Gastroenterology and the Digestive System

Publisher: MedDocs Publishers LLC

Online edition: <http://meddocsonline.org/>

Copyright: © Das D (2023). This Article is distributed under the terms of Creative Commons Attribution 4.0 International License

Case

A 28-year-old male patient presented to us with chief complaints of mild intermittent non radiating pain abdomen, in right lower abdomen for 2 months, along with significant weight loss. Routine investigations were done which was suggestive of Anaemia (Hb 10gm/dl), lower serum albumin 3.4mg/dl, increased ESR. Pulmonary Koch was excluded by CECT chest reporting Normal findings. CECT with CT enterography done that revealed ileocecal thickening, ?ileocecal Fistula along with mesenteric & retroperitoneal lymphadenopathy.

Ileo-colonoscopy was advised for further evaluation that showed caecal cicatrisation (? sequelae from previous ulcers) near IC valve. No definitive ulcers/ erosions noted in terminal ileum and cecum. There was another large fistulous opening near the IC valve connecting the cecum to ileum, which looked like additional ileocecal valve. Biopsy was taken around the fistulous opening, sent for HPE and GeneXpert/culture test. Biopsy findings came out to be inconclusive as non-specific ileitis, whereas GeneXpert was positive with Sensitive to Rif/H. Subsequently he was started on ATT which he responded well symptomatically and then continued for full course of 9 months.

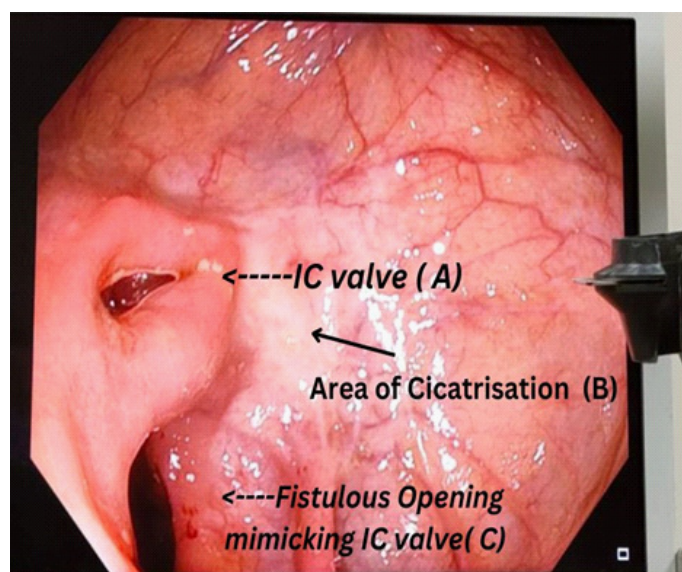


Figure 1: (A) Patulous Ileocecal Valve (B) whitish cicatrised area probably sequelae from previous ulcers, (C) fistulous opening into ileum from cecum near the IC valve.



Discussion

Ileocecal fistula mimicking as ileo-caecal opening is extremely rare finding. No case report has been reported yet. On literature review 3 cases have been reported, but 2 of them were found in cases of Behcet disease, and the other was due to histoplasmosis in an AIDS patient. This case report highlights this finding in a patient of ileo-caecal tuberculosis among other different possible presentations, which is of importance to keep in mind especially in an endemic country like India.

References

1. Utsami T, Hiramatsu Y, Miyamoto S et al. Double ileo-caecal valve. *Gastrointestinal endoscopy*. 2019; 89: 201-202.
2. Chang HK, Kim JS, Chung HR. Ileocecal ulcer with a cecocolic fistula in Behçet's disease. *Korean J Intern Med*. 2000; 15: 99-101
3. Zarrinpar A, Lin GY, Lonergan JT. A rare cause of an ileocecal fistula in an AIDS patient. *Gastrointestinal infection by Histoplasma capsulatum infection identified with internal transcribed spacer primer sets*. *Gastroenterology*. 2013; 144: 697, 857-858.