



# Conjunctival Lymphoma Revealing a Small Cell Lymphoma

**Lazaar Hamza\***; Meryem Sefrioui; Taha Boutaj; Najoua El-Moubarik; Boutayna Azarkan; Nouredine Boutimzine  
Ophthalmology A, Hôpital Des Spécialités Rabat, University Mohamed V, Morocco.

**\*Corresponding Authors: Lazaar Hamza**

Ophthalmology A, Hôpital Des Spécialités Rabat, University Mohamed V, Morocco.  
Tel: +2120623204877; Email: lzhamz22@gmail.com

Received: Apr 08, 2023

Accepted: May 03, 2023

Published Online: Nov 07, 2023

Journal: Annals of Ophthalmology and Visual Sciences

Publisher: MedDocs Publishers LLC

Online edition: <http://meddocsonline.org/>

Copyright: © Hamza L (2023). *This Article is distributed under the terms of Creative Commons Attribution 4.0 International License*

## Clinical Image Description

We report the case of a 52 -year-old male patient with no particular previous history, presenting to the emergency ophthalmology with Unilateral conjunctival mass in the right eyes that had progressively increased over the last two months.

The best-corrected visual acuity was 10/10 assessed with Snellen scale in both eyes.

Slit lamp examination showed an high-vascularized “salmon pink” conjunctival lesion in the superior temporal bulbar conjunctiva of the right eye (**Figure 1**). The rest examination of the anterior segment of both eyes showed a clear cornea with a deep calm anterior chamber, an cortical cataract grade 1.

The posterior segment was normal in both eyes.

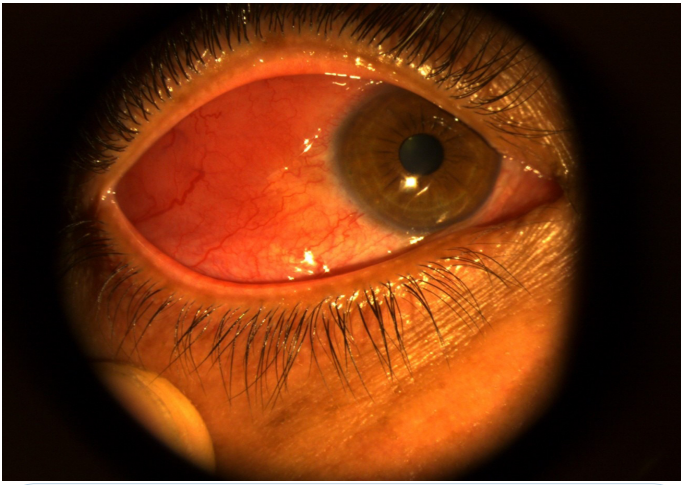
The examination of the lymph node areas reveals a 2 cm right supraclavicular lymphadenopathy.

An orbital MRI was performed, which showed superior eyelid infiltration surface with iso-intense T2 signal and Moderate Enhancement after Gadolinium Injection as well as infiltration of the right main lacrimal gland, with Mild Infiltration of Intraconal Fat.

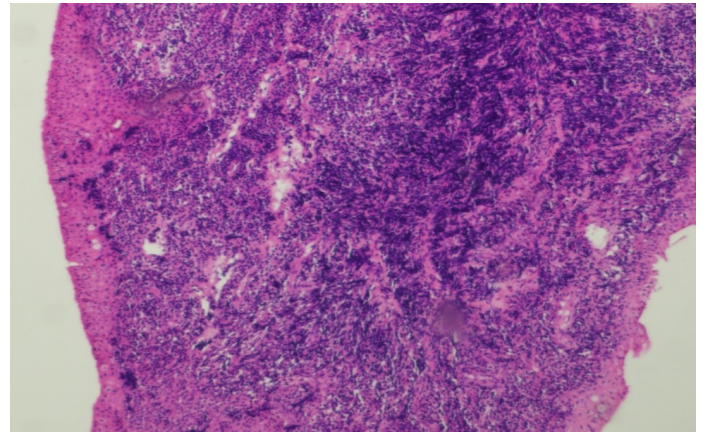
A conjunctival biopsy was performed with complementary immunohistochemistry, revealing a marginal zone B-cell lymphoma (**Figure 2**). Then referred to the hematology/oncology department for chemotherapy treatment.



**Cite this article:** Lazaar H, Meryem S, Taha B, El-Moubarik N, Azarkan B, et al. Conjunctival Lymphoma Revealing a Small Cell Lymphoma. *Ann Ophthalmol Vis Sci.* 2023; 6(2): 1042.



**Figure 1:** Characteristic Clinical Features of conjunctival Lymphoma with Salmon-Pink, Painless Conjunctival Thickening”.



**Figure 2:** Histological section showing dense lymphoid proliferation composed of small cells.