



Posterior Lenticonus Revealed by Congenital Cataract

Meryem Sefrioui*; Saoiabi Yahya; Hamza Lazaar; Salma Hamidi; Narjisse Taouri; Lalla Ouafa Cherkaoui
Ophthalmology A, Hôpital Des Spécialités Rabat, University Mohamed V, Morocco.

***Corresponding Authors: Meryem Sefrioui**

Ophthalmology A, Hôpital Des Spécialités Rabat, University Mohamed V, Morocco.
Tel: +2120663058316; Email: meryemsefri@gmail.com

Received: Apr 08, 2023

Accepted: May 03, 2023

Published Online: May 10, 2023

Journal: Annals of Ophthalmology and Visual Sciences

Publisher: MedDocs Publishers LLC

Online edition: <http://meddocsonline.org/>

Copyright: © Sefrioui M (2023). *This Article is distributed under the terms of Creative Commons Attribution 4.0 International License*

Clinical Image Description

We report the case of a 4-year-old, only child in his family, with no personal or family history. He consulted for a leukocoria of the left eye never explored before.

Ophthalmologic examination of the left eye revealed visual acuity reduced to light perception. The ocular tonus was 14mmhg. Slit lamp examination revealed a cataract (**Figure 1**) with inaccessible fundus. The examination of the right eye was strictly normal. Ocular ultrasound revealed a hyperechogenic lens, with a posterior bulge suggestive of a lenticonus, and for the posterior segment, there were no other anomalies (**Figure 2**). An etiological workup was performed (urinalysis and proteinuria), it came back normal. In addition, the audiogram was normal. Management consisted of cataract surgery by phacoemulsification with posterior capsulorhexis and implantation in the bag, followed by treatment of the amblyopia.

Posterior lenticonus is an ectasia of the posterior lens capsule that manifests as a circumscribed round or oval bulge of the posterior surface of the lens.

It usually presents as a sporadic unilateral anomaly with a female predominance, sometimes associated with a congenital cataract. In the RUSSELL-EGGITT series, posterior lenticonus was associated with a unilateral congenital cataract in 14% of children.

Other rare ocular associations include microphthalmia, microcornea, persistence of the vascular system of the anterior hyaloid, and uveal colobomas. It may also occur in the setting of Alport syndrome and Lowe's oculocerebrorenal syndrom.



Cite this article: Meryem S, Saoiabi Y, Hamza L, Salma H, Narjisse T, et al. Posterior Lenticonus Revealed by Congenital Cataract. *Ann Ophthalmol Vis Sci.* 2023; 6(1): 1036.

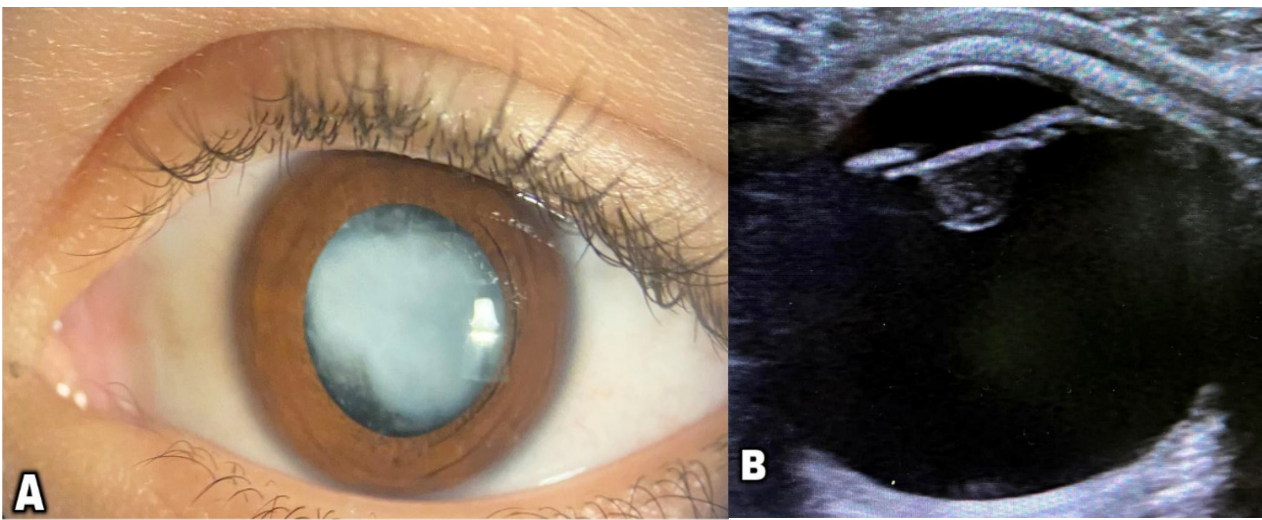


Figure 1: (A) Slit lamp examination of the left eye: congenital cataract; (B) Ultrasound image of the left eye: Conical deformation of the posterior surface of the lens suggesting a posterior lenticonus.