



Unilateral Florid Proliferative Radiation Retinopathy in Orbital DLBCL

Rahul P Vijaykumar; Nawazish Shaikh*; Rohan Chawla

Dr Rajendra Prasad Centre for ophthalmic sciences, All India Institute of Ophthalmic Sciences, New Delhi, India, Pin- 110029

*Corresponding Authors: Nawazish Shaikh

Department of Ophthalmology, Dr Rajendra Prasad Centre for ophthalmic sciences, All India Institute of Ophthalmic Sciences, New Delhi, India.

Tel: +919920098673; Email: shaikh.nawazish@gmail.com

Received: Apr 26, 2023

Accepted: May 22, 2023

Published Online: May 29, 2023

Journal: Annals of Ophthalmology and Visual Sciences

Publisher: MedDocs Publishers LLC

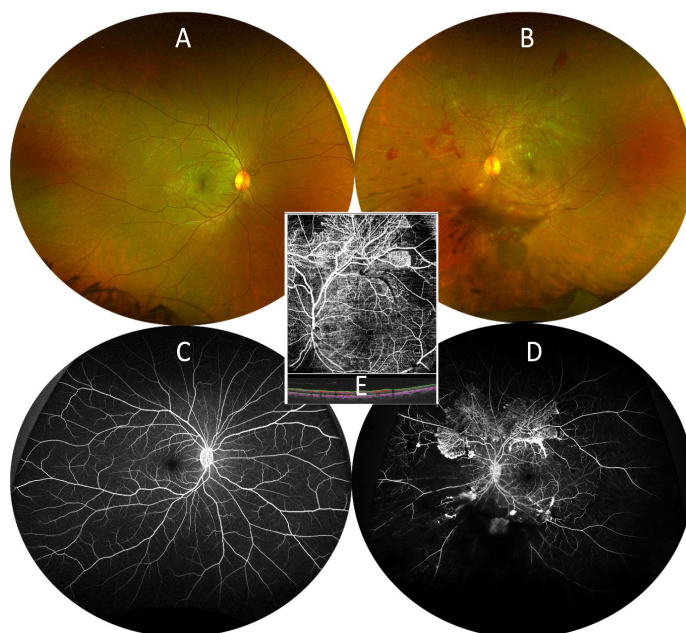
Online edition: <http://meddocsonline.org/>

Copyright: © Shaikh N (2023). *This Article is distributed under the terms of Creative Commons Attribution 4.0 International License*

Keywords: Proliferative retinopathy; Radiation Retinopathy; Orbital lymphoma.

Introduction

A 35-year-old male presented with complaints of diminution of vision and floaters in OS for 2 months. Best corrected visual acuity was 20/20 and 20/80 in OD and OS respectively. Fundus of OD was normal (A,C) with florid neovascularization at the posterior pole with dispersed vitreous hemorrhage in OS (B). Fundus fluorescein angiography and OCT-A revealed extensive neovascularization and capillary non-perfusion areas in OS (D,E). Past history revealed abaxial proptosis in OS and diagnosed orbital diffuse B cell lymphoma (DLBCL) for which he underwent chemotherapy and EBRT with cumulative dose of 450Gy over 3 weeks. Pan-retinal photocoagulation was advised in OS.



Cite this article: Vijaykumar RP, Nawazish S, Rohan C. Unilateral Florid Proliferative Radiation Retinopathy in Orbital DLBCL. *Ann Ophthalmol Vis Sci.* 2023; 6(1): 1039.