



Motion Correction Significantly Reduces Motion Artifact in both Cardiac Structures and Coronary Vessels in High Heart Rate CCTA: Evaluation of the Performance of Second Generation Intra-Cycle Motion Correction Algorithm

Kashif Shaikh^{1*}; Sion K Roy¹; Ahmed Shafter¹; Thomsen Brian²; Darin Okerlund²; Matthew J Budoff^{1*}

¹Lundquist Institute of Biomedical Research Institute at Harbor-UCLA Medical Center, USA.

²General Electric (GE).

***Corresponding Author(s): Matthew J Budoff**

Lundquist Institute of Biomedical Research Institute at Harbor-UCLA Medical Center, 1124 W Carson Street, Torrance CA 90502, USA.

Email: kashifabbasshaikh@gmail.com

Abstract

Introduction: Intra-cycle motion correction (SnapShot Freeze, SSF, GE Healthcare) has been an invaluable tool to correct for coronary motion in cardiac CT data acquired from a single rotation. Recently, a second-generation intra-cycle motion correction algorithm (SnapShot Freeze 2, SSF 2, GE Healthcare) has been introduced which provides whole-heart motion correction – including both coronary motion as well as motion in other cardiac structures (e.g., valves, chambers, great vessels). The purpose of this study was to evaluate the performance of this algorithm in correcting for motion across the cardiac structures.

Methods: Sixty Coronary CT Angiography (CCTA) clinical cases without heart rate control were included in this evaluation. These images were acquired using 16cm collimation (0.28 sec gantry rotation speed) Revolution CT, 4cm collimation (0.35 sec gantry rotation speed) and GSI dual energy acquisition modes (0.35 sec gantry rotation speed) on the Revolution HD & Revolution GSI systems. Images were reconstructed both without motion correction (STND) and with motion correction (SSF2). Three level 3 readers according to the SCCT guidelines read each case. Image quality was rated for each coronary artery (RCA, LM, LAD, LCX) and for the non-coronary structures according to the following Likert scale: 5= Pristine, no motion present, interpretable, 4= Minor motion, interpretable, 3= Motion apparent, interpretable, 2= Significant motion, limited-interpretability, 1= Completely unreadable because of motion, non-diagnostic

Received: Nov 18, 2022

Accepted: Dec 06, 2022

Published Online: Dec 08, 2022

Journal: Journal of Clinical Images

Publisher: MedDocs Publishers LLC

Online edition: <http://meddocsonline.org/>

Copyright: © Shaikh K (2022). *This Article is distributed under the terms of Creative Commons Attribution 4.0 International License*

Cite this article: Kashif S, Roy SK, Ahmed S, Brian T, Okerlund D, et al. Motion Correction Significantly Reduces Motion Artifact in both Cardiac Structures and Coronary Vessels in High Heart Rate CCTA: Evaluation of the Performance of Second Generation Intra-Cycle Motion Correction Algorithm. J Clin Images. 2022;5(2): 1135.



Results: Mean heart rate in the CCTA data was 80.9 bpm (range 70-116 bpm). Average Likert scores for the STND reconstructions were 2.71, 4.07, 2.94, 2.86, 3.47 in the RCA, LM, LAD, LCX and non-coronary structures respectively. Average Likert scores for the SSF2 reconstructions were 4.52, 4.84, 4.50, 4.51, and 4.61 for the RCA, LM, LAD, LCX and non-coronary structures respectively.

Conclusions: Improvements in mean scores were most pronounced in the RCA, followed by the LAD and LCX using this new algorithm. Snap Shot Freeze 2 leads to marked improvement in image quality, despite high resting heart rate. This will allow, for the first time, whole heart coverage without need for heart rate control in a vast majority of cases.

Introduction

Several studies have shown high diagnostic accuracy of Cardiac Computed tomography angiography (CCTA) for diagnosis of coronary artery disease when compared to other non-invasive as well as invasive angiography [1,2]. Moreover, CCTA is routinely utilized pre-operatively in transcatheter aortic and mitral valve replacement procedures [3]. Despite advancement in technology, CCTA artifacts such as coronary motion can significantly reduce diagnostic accuracy [4]. To address coronary motion artifacts, GE Healthcare introduced previously an intra-cycle motion correction software (SnapShot Freeze, SSF). However, while SSF has been demonstrated to reduce motion artifacts in the coronary arteries, it does not address motion artifacts that may remain in non-coronary structures of the heart such as valves, chambers, great vessels, and the myocardium [3]. Artifacts in these other structures may have implications for valve and myocardial assessment.

To address this, GE Healthcare has now developed a second-generation intra-cycle motion correction algorithm (SnapShot Freeze 2, SSF2) to perform “whole heart” motion correction; that is, correcting motion not only in the coronaries but in other cardiac structures as well. Similar to the previous SSF algorithm, SSF2 uses the information from adjacent cardiac phases, available from a single rotation, to characterize motion at the prescribed target phase. With a fully automated technique, the SSF2 algorithm searches each region of the image volume for a local motion path that is consistent with the subset of measured data that passes through that portion of the image volume. Once the motion path is known, the data is decomposed into a series of datasets according to the time at which the corresponding projection rays were measured. Each image volume in the series is then spatially deformed by the motion field that maps the motion state from the respective time to the central reference time, which is given by the prescribed cardiac phase. As whole heart correction requires motion characterization along all three axes, this also provides greater robustness in coronary motion correction itself, especially helpful for extreme motion scenarios and motion paths predominantly along the z-axis.

The purpose of this study was to assess the performance of this second-generation intra-cycle motion correction algorithm in performing whole heart motion correction in which motion artifacts are corrected in the coronary arteries as well as in non-coronary structures.

Methods

Retrospective coronary CT data was collected in which the patient populations had elevated heart rate (HR>65 bpm) at the time of the CT scan. This data with higher heart rates was selected because it was more likely to have associated motion artifact. Data from multiple systems (all manufactured by GE Healthcare) was included, including a system with 16cm collimation and 0.28sec gantry rotation speed (Revolution CT), 4cm collimation and 0.35sec gantry rotation speed (Revolution HD), and then the same 4cm system only acquired in dual energy acquisition mode (Revolution GSI).

Images without correction were reconstructed on the relevant commercially available CT scanner console (STND). The SSF2 algorithm was then applied to these to create the corrected images (SSF2).

Reader assessment

All images were transferred to a single vendor workstation to provide standardized postprocessing for both scanner acquisitions (AW 4.7, GE Healthcare). Three SCCT level-3 trained readers read all the images at a central reading center (Los Angeles Biomedical Research Institute at Harbor-UCLA in Torrance, California). For both the STND and SSF2 images, the readers were asked to rate the motion artifact in the Left Anterior Descending (LAD), Left Main (LM), Left Circumflex (LCX), and Right Coronary (RCA) arteries as well as the motion artifact across the non-coronary structures (i.e. great vessels, valves and chambers, myocardium) according to the following Likert scale:

- 5= Pristine, no motion present, interpretable
- 4= Minor motion, interpretable
- 3= Motion apparent, interpretable
- 2= Significant motion, limited-interpretability
- 1= Completely unreadable because of motion, non-diagnostic

Statistical analysis

Overall frequency of motion artifact Likert scores was tabulated. In order to test for significance in motion artifact improvement, a paired two-tailed t-test was used to test the null hypothesis that the mean motion artifact score between the STND and SSF2 images is the same. This test was done at the vessel level, for the non-cardiac structures, across all vessels, and at the patient level. In all cases a p value of less than 0.05 was considered significant.

Results

A total of 60 cases were included in this study with mean HR of 80.9 BPM (range 60-116) (**Table 1**). Average Likert scores for the STND reconstructions were 2.50, 4.13, 3.17, 3.01, 3.20 in the RCA, LM, LAD, LCX and non-coronary structures respectively. Average Likert scores for the SSF2 reconstructions were 4.38, 4.84, 4.57, 4.47, and 4.57 for the RCA, LM, LAD, LCX and non-coronary structures (p<0.001) respectively (**Table 2**) The change in mean motion artifact Likert score was highest in RCA and LCXv (**Figure 1**).

There was consistent improvement in all vessels and non-coronary structures from STND to SSF2 across all readers with various CT scanners (**Figure 2**). **Figure 3** shows an example of impact of SSF2 correction algorithm on improvement in image quality.

Table 1: Shows distribution of sixty cases scanned on different platforms and mean heart rates.

System	# of cases	Mean heart rate (min-max) BPM
16cm collimation (0.28 sec gantry rotation speed)	30	84.5 (70-116)
4cm collimation (0.35 sec gantry rotation speed)	20	80.3 (66-106)
4cm collimation (0.35 sec gantry rotation speed) with GSI	10	70.3 (60-87)
	Total: 60	Overall: 80.9 (60-116)

Table 2: Shows the mean Likert scale across each assessed vessel and the non-coronary structures, and further shows the results split by CT platform type as well as overall.

		RCA	LM	LAD	LCX	All coronaries	Non-coronary
16cm, 0.28sec gantry rotation speed	STND	2.71	4.06	2.94	2.86	3.14	3.47
	SSF2	4.52	4.84	4.50	4.41	4.57	4.61
	p-value	< 0.001	< 0.001	< 0.001	< 0.001	< 0.001	<0.001
4cm, 0.35sec gantry rotation speed	STND	2.37	4.43	3.48	3.32	3.40	3.53
	SSF2	4.25	4.95	4.72	4.6	4.63	4.45
	p-value	< 0.001	< 0.001	< 0.001	< 0.001	< 0.001	<0.001
4cm, 0.35sec gantry rotation speed, GSI mode	STND	2.13	3.73	3.20	2.87	2.98	3.43
	SSF2	4.20	4.60	4.50	4.40	4.43	4.30
	p-value	< 0.001	< 0.001	< 0.001	< 0.001	< 0.001	<0.001
All platforms	STND	2.50	4.13	3.17	3.01	3.20	3.48
	SSF2	4.38	4.84	4.57	4.47	4.57	4.51
	p-value	<0.001	<0.001	<0.001	<0.001	<0.001	<0.001

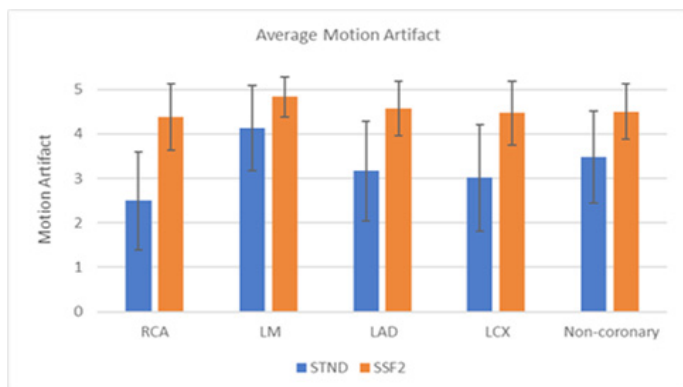


Figure 1: Average motion artifact improvement for all patients across different platforms.

Discussion

Our results showed that there was significant improvement in motion grades in all vessels and non-coronary structures across different GE platforms. Furthermore, this improvement was consistent across all CT readers. The last two decades have seen substantial improvement in CCTA technology [2,5-7]. Nonetheless, motion artifact remains one of the significant limiting factors in accurate evaluation of CCTA [4,8]. Previously published reports have shown that motion correction algorithms such as SSF improve interpretability, image quality and diagnostic accuracy [9,10].

However, these studies reported only on improvement in motion in coronary arteries. To our knowledge, the current study is the first to evaluate the effect a novel motion correction algorithm, i-e SSF2, on coronary as well as non-coronary structures. Although a lower heart rate is recommended to eliminate motion artifact, it is not always possible, especially in challenging clinical patients. Furthermore, patients undergo-

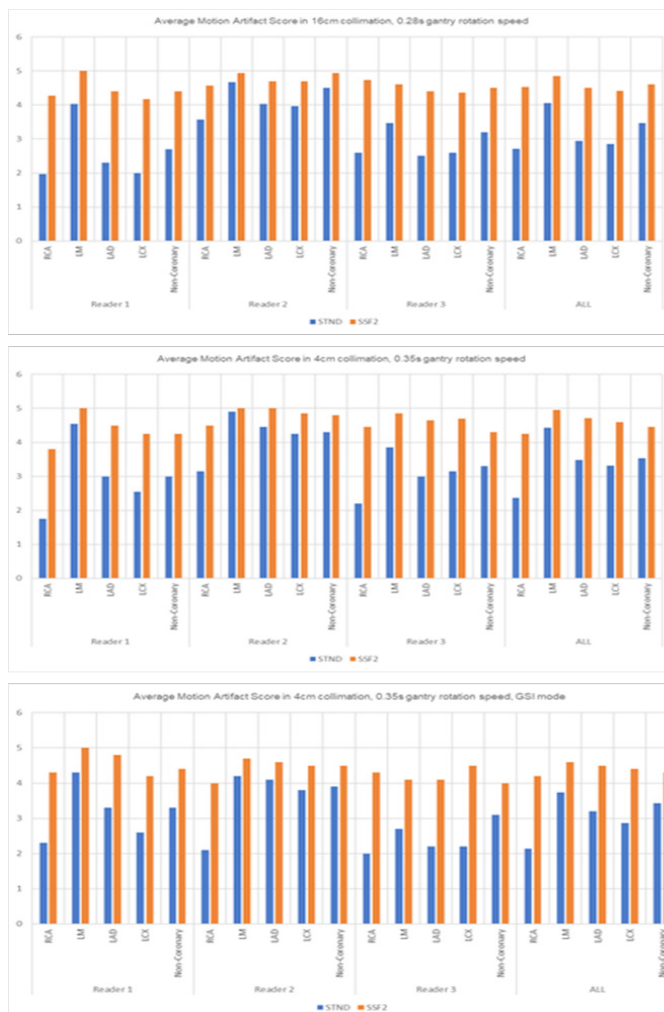


Figure 2: Shows average motion artifact scores for standard and SSF2 for three readers across different platforms.

ing preoperative CT evaluation for TAVR have high prevalence of active atrial fibrillation and higher heart rates with high frequency of prior coronary artery disease. Leipsic et al. [10] found 14% prevalence of atrial fibrillation at time of coronary CTA in patients being evaluated for TAVR with mean HR of >70 beats/min. Artifacts due to high heart rate and HR variability remain central causes of studies considered to be non-diagnostic, and motion artifact alone may lead to as many as 12% of coronary segments being non-assessable [1,4,8,9]. The SSF2 motion correction algorithm helps manage a higher baseline heart rate by determining the motion path through different phases and adaptively compressing the temporal window to the central reference time. Unlike multi-segment reconstruction, this algorithm detects and corrects motion within a single heart cycle and as such is less susceptible to heart rate variability.

SSF2, which not only corrects for motion artifact in coronaries but as well as in non-coronary structures such as aortic valve, might become particularly important for accurate valve annulus sizing and assessment of the myocardium. Future studies would be needed to evaluate the impact of the SSF2 algorithm on diagnostic accuracy on coronary as well as the impact in non-coronary evaluation.

Our study has some limitations that should be acknowledged. First, taking into account when scoring image quality, there may be conflation between different artifacts that effect the score. For instance, both motion and noise artifacts may decrease when using SSF2 reconstruction. Thus, it is hard to assess the contribution of noise reduction in improvement of the overall image quality. Secondly, the readers were not blinded to whether they were reading the corrected (SSF2) or uncorrected (STND) images. Other limitation include smaller sample size. Furthermore, we did not have coronary angiography data to compare our CCTA readings and were therefore unable to determine whether diagnostic accuracy is improved with this algorithm.

References

1. Miller JM, Rochitte CE, Dewey M, Arbab-Zadeh A, Niinuma H, et al. Diagnostic performance of coronary angiography by 64-row CT. *New England Journal of Medicine*. 2008; 359: 2324-2336.
2. Budoff MJ, Dowe D, Jollis JG, Gitter M, Sutherland J, et al. Diagnostic performance of 64-multidetector row coronary computed tomographic angiography for evaluation of coronary artery stenosis in individuals without known coronary artery disease: results from the prospective multicenter ACCURACY (Assessment by Coronary Computed Tomographic Angiography of Individuals Undergoing Invasive Coronary Angiography) trial. *Journal of the American College of Cardiology*. 2008; 52: 1724-1732.
3. Leipsic J, Labounty TM, Hague CJ, John Mancini GB, O'Brien JM, et al. Effect of a novel vendor-specific motion-correction algorithm on image quality and diagnostic accuracy in persons undergoing coronary CT angiography without rate-control medications. *Journal of cardiovascular computed tomography* 2012; 6: 164-171.
4. Andreini D, Pontone G, Ballerini G, Quaglia C, Nobili E, et al. Feasibility and diagnostic accuracy of 16-slice multidetector computed tomography coronary angiography in 500 consecutive patients: critical role of heart rate. *The international journal of cardiovascular imaging*. 2007; 23: 789-801.
5. Beller E, Meinel FG, Schoeppe F, Kunz WG, Thierfelder KM, et al. Predictive value of coronary computed tomography angiography in asymptomatic individuals with diabetes mellitus: Systematic review and meta-analysis. *J Cardiovasc Comput Tomogr* 2018; 12: 320-328.
6. Goldstein JA, Chinnaiyan KM, Abidov A, Achenbach S, Berman DS, et al. The CT-STAT (Coronary Computed Tomographic Angiography for Systematic Triage of Acute Chest Pain Patients to Treatment) trial. *Journal of the American College of Cardiology*. 2011; 58: 1414-22.
7. Hoffmann U, Truong QA, Schoenfeld DA, Chou ET, Woodard PK, et al. Coronary CT angiography versus standard evaluation in acute chest pain. *The New England journal of medicine*. 2012; 367: 299-308.
8. Herzog C, Arning-Erb M, Zangos S, Eichler K, Hammerstingl R, et al. Multi-detector row CT coronary angiography: influence of reconstruction technique and heart rate on image quality. *Radiology*. 2006; 238: 75-86.
9. Andreini D, Lin FY, Rizvi A, Cho I, Heo R, et al. Diagnostic Performance of a Novel Coronary CT Angiography Algorithm: Prospective Multicenter Validation of an Intracycle CT Motion Correction Algorithm for Diagnostic Accuracy. *AJR American journal of roentgenology* 2018; 210: 1208-1215.
10. Leipsic J, Labounty TM, Hague CJ, John Mancini GB, M O'Brien J, et al. Effect of a novel vendor-specific motion-correction algorithm on image quality and diagnostic accuracy in persons undergoing coronary CT angiography without rate-control medications. *J Cardiovasc Comput Tomogr*. 2012; 6: 164-71.