



Periprosthetic fracture of right femur and internal fixation and loosening after replacement of right hip joint

Xiong Ying¹; Md Ariful Haque^{1*}; Wu Tong¹; Gan XueWen¹; Mahedi Hasan²

¹Department of Orthopedic Surgery, Yanan Hospital Affiliated to Kunming Medical University, Kunming, Yunnan, China.

²North China University of Science and Technology, Tangshan, Hebei, China.

***Corresponding Author(s): Md Ariful Haque**

Department of Orthopedic Surgery, Yanan Hospital
Affiliated to Kunming Medical University, Kunming,
Yunnan, China.

Tel: +86 1848 711 2849

Email: arifulhaque58@gmail.com

Received: Apr 10, 2020

Accepted: May 15, 2020

Published Online: May 19, 2020

Journal: Journal of Clinical Images

Publisher: MedDocs Publishers LLC

Online edition: <http://meddocsonline.org/>

Copyright: © Haque A (2020). *This Article is distributed under the terms of Creative Commons Attribution 4.0 International License*

Clinical image description

Li Zhuxian, 78 years old, Chinese woman, got admitted to the hospital with the complain of pain, swelling and restricted movement in the right lower limb for about 8 hours.

The patient stated that she fall down from the bed carelessly in the morning, thereafter she was suffering from the pain, swelling, restricted movement also Dark coloration of skin on the affected site. It was not associated with nausea, vomiting, or abdominal pain. After the injury she got admitted to orthopedic hospital. A plain X-ray of right hip & knee joint was done.

X-ray film shows a Periprosthetic fracture on the proximal

part of right hip bone and a fracture in the distal part of the right hip bone. The swelling of the middle part of right greater brittleness is obvious which can touch the obvious sense of bone friction. The percussion pain and tenderness of the right knee joint are positive. Right knee joint movement is limited, movement of the ankle & toes were good.

Physical examination shows that shortening of right lower limb & the limb was internally rotated, swelling in the middle part of right thigh, the obvious sense of bone friction can be felt. Percussion tenderness positive on right knee joint & obvious sense of bone loss and right knee joint movement is limited. All the peripheral pulses of lower limb were intact, motor and sensory activities were good.



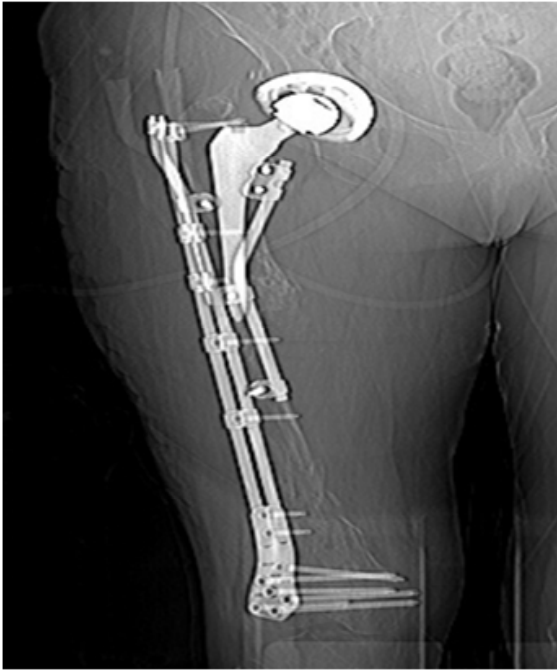

Figure 1: After repair plate screw X-ray.

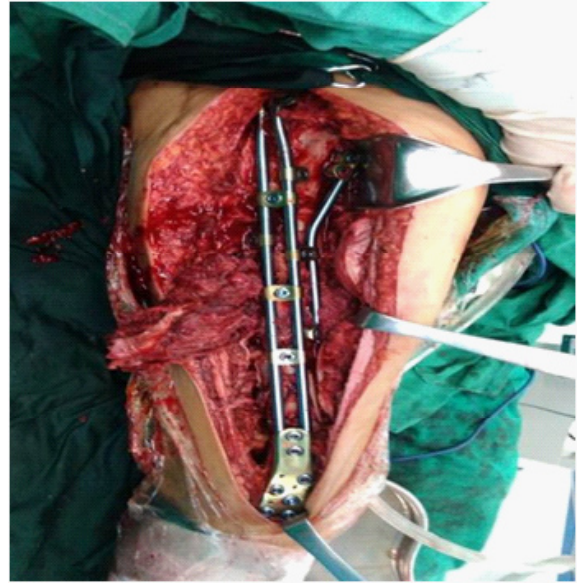


Figure 3: Preoperative period of screw setting.

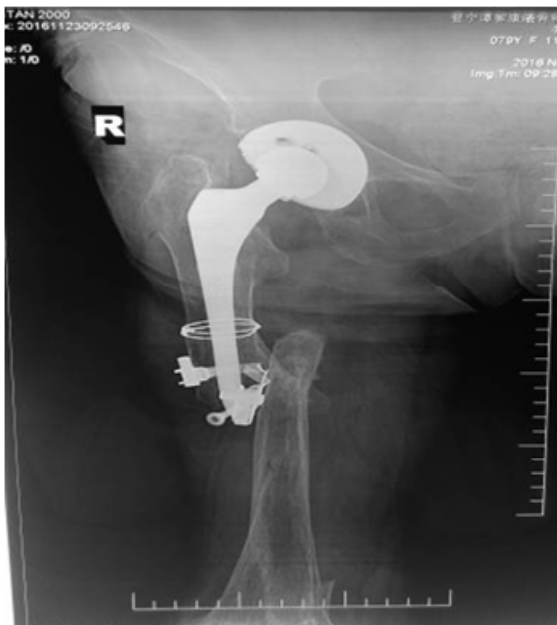

Figure 2: Plain X-ray right hip joint showing fracture of proximal end of femur.