



Bone Marrow Tuberculosis

Rameesha Hussain¹; Muhammad Fahad^{2*}; Ayesha Zahid³

¹MBBS, Peterborough City Hospital, UK.

²MBBS, MRCP, Peterborough City Hospital, UK.

³MBBS, Services Hospital, Lahore.

***Corresponding Author(s): Muhammad Fahad**

Peterborough City Hospital, UK.

Tel: +447746641430;

Email: muhammadfahad.dr@gmail.com

Abstract

Mycobacterium Tuberculosis (MTB) is common in South Asian subcontinent; affects the lungs mostly but can affect any organ of the body. It is from the family Mycobacteriaceae that can cause devastating illness in an immune-compromised patient but can be equally harmful in immune-competent individuals. It spreads through droplets.

Received: Nov 06, 2021

Accepted: Dec 06, 2021

Published Online: Dec 09, 2021

Journal: Journal of Radiology and Medical Imaging

Publisher: MedDocs Publishers LLC

Online edition: <http://meddocsonline.org/>

Copyright: © Fahad M (2021). This Article is distributed under the terms of Creative Commons Attribution 4.0 International License

Introduction

A 56 year old female presented with complaints of fever with night sweats, weight loss with progressively worsening exertional breathlessness for 3 months. She was an ex-smoker with a history of 30 pack years. She did have a history of Tuberculosis (TB) contact as her father was diagnosed with pulmonary TB about 20 years back. Past medical history was unremarkable. There was no family history of any cancer. On examination she was pale, febrile but with unremarkable cardiovascular and pulmonary examinations. A routine set of blood works was done that showed pancytopenia with raised ESR. Peripheral film did not show any abnormal cells. Retic count was also low. Chest X-ray was normal. CT chest showed prevascular, pretracheal and para-aortic lymph nodes (figure.1) but no lesion in lung parenchyma. Bone marrow biopsy showed granuloma with caseous necrosis. PCR (Gene Xpert) was done which yielded MTB. She was started on anti-tuberculosis treatment and her symptoms settled and cell lines on full blood counts improved after 3 weeks.

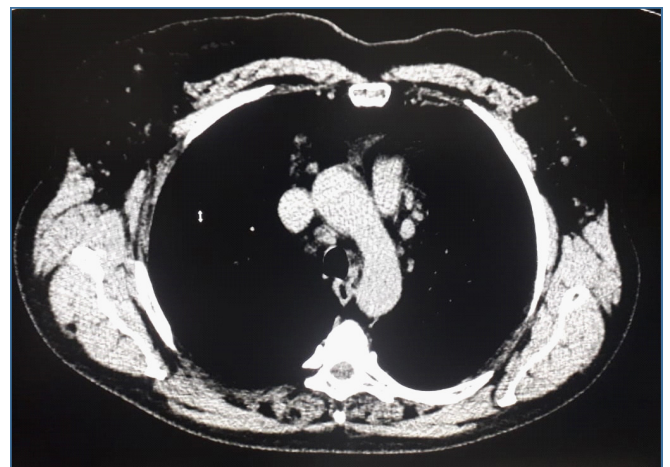


Figure 1

Cite this article: Hussain R, Fahad M, Zahid A. Bone Marrow Tuberculosis. J Radiol Med Imaging. 2021; 4(2): 1061.



Discussion

MTB infections mostly cause symptoms of lungs and intestine. However, bone marrows infiltration and pancytopenia in absence of symptoms of other body systems is rare. Mortality varies depending upon the site of infection, drug resistance and patient co-morbidity. Bone marrow infection can present with symptoms related to drop in one cell line or all the three cell lines. Symptoms can range from fatigue, exertional breathlessness, dizziness, fever, bruises or bleeding from any site. Patients may also exhibit other signs and symptoms if other tissues are involved. Investigation for diagnosis depends upon the tissue involved. In case of bone marrow involvement, Bone marrow examination and PCR (GENEXPERT) are the investigations of choice. Treatment is same as pulmonary tuberculosis, anti-tuberculosis drugs for 6 months. Early recognition and treatment is the key to prevent complications and infection affecting other body organs.

Summary

To summarize, it is quite rare for MTB infection to present primarily with symptoms of bone marrow suppression. This case report shows ability of MTB to attenuate bone marrow and suppress one or more than one cell lines in an otherwise healthy individual.