



Idiopathic Intracranial Hypertension

Seeratafshan Kazi*; **Shafiulla Khaji**

East Lancashire NHS trust, UK.

***Corresponding Author(s): Seeratafshan Kazi**

East Lancashire NHS trust, East Lancashire Trust, United Kingdom.

Tel: 00447428527368, Fax: 0044428527368;

Email: drseeratkazi2007@gmail.com

Abstract

Idiopathic intracranial hypertension or pseudotumour cerebri, is a neurological disorder characterized by symptoms and signs of raised intracranial pressure with no other cause of intracranial hypertension demonstrated on neuroimaging or other investigations. It is commonly seen in obese females. We are presenting a case of idiopathic intracranial hypertension in a female who was on steroid and immunosuppressants for eosinophilic granulomatosis and had gained weight possibly due to long term use of steroids.

Received: Sep 27, 2021

Accepted: Oct 20, 2021

Published Online: Oct 22, 2021

Journal: Journal of Radiology and Medical Imaging

Publisher: MedDocs Publishers LLC

Online edition: <http://meddocsonline.org/>

Copyright: © Kazi S (2021). *This Article is distributed under the terms of Creative Commons Attribution 4.0 International License*

Clinical image description

T A 22-yr-old Caucasian female presented with headache, vomiting and double vision for 1 week. She has background history of eosinophilic granulomatosis with polyangiitis for which she was on Tablet prednisolone and azathioprine since one and half year apart from inhaler for Asthma. She has been under care of rheumatologist and pulmonologist. She had high BMI. The visual acuity was 0.2 Log MAR right eye and 0.1 Log MAR left eye. Anterior segment examination was within normal limits and there was bilateral abducens nerve (sixth cranial nerve) paresis with bilateral significant optic disc swelling with retinal hemorrhages and cotton wool spots to suggest Grade 4 pap-

illedema. Visual field examination showed inferior visual field defect more in left eye than right. She had no other neurological deficits. Opening pressure was more than 34 cm of H₂O on lumbar puncture. Magnetic Resonance Imaging (MRI) and Magnetic Resonance Venography (MRV) demonstrated prominence of the sub-arachnoid spaces surrounding the left optic nerve and there was no intracranial hemorrhage or space occupying lesion. There was extensive mucosal thickening throughout the paranasal sinuses suggesting sinusitis. She was started on acetazolamide for Idiopathic Intracranial Hypertension (IIH) due to possible steroid induced weight gain.



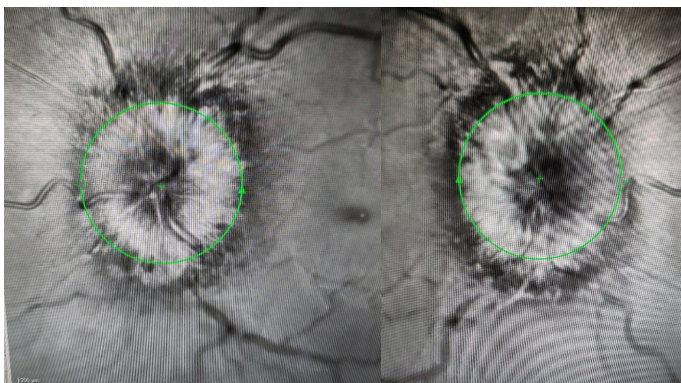


Figure 1: Left and Right optic disc showing disc swelling.

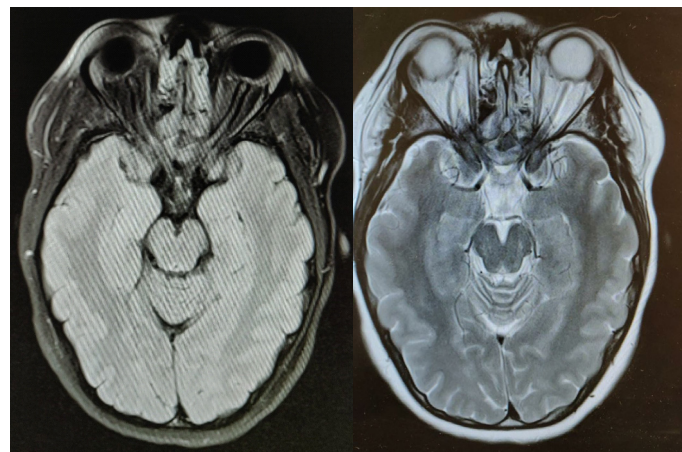


Figure 2: MRI showing prominent subarachnoid space and flattening of posterior sclera.

Idiopathic intracranial hypertension also known as ‘Pseudotumor cerebri’ is a condition commonly seen in childbearing age female who are overweight. These patients present with headache, blurring of vision and diplopia. Consciousness and cognition are not affected. The Cause of IIH is often not known or secondary to venous sinus thrombosis or due to drugs e.g., Nitrofurantoin, minocycline, vitamin A. The major risk factor is high BMI (Body Mass Index). Lumbar puncture shows high opening pressure with normal CSF composition. Neuroimaging such as MRI with MRV are preferred to rule out any other intracranial cause of Increased Intracranial Pressure (ICP). Widening of perioptic subarachnoid space, vertical tortuosity of the optic nerves, flattening of posterior sclera and or empty sella may be seen on neuroimaging. Treatment includes weight loss, acetazolamide and or loop diuretics. Lumboperitoneal shunts or optic sheath fenestration can be considered if vision deteriorates. Patients require regular ophthalmology follow-ups for vision and visual field assessments.